



P-ISSN: 2394-1685
E-ISSN: 2394-1693
Impact Factor (ISRA): 5.38
IJPESH 2016; 3(4): 07-09
© 2016 IJPESH
www.kheljournal.com
Received: 03-05-2016
Accepted: 04-06-2016

Mahendra R Patait
Prof Head Dept of Oral Medicine
and Radiology, SMBT Dental
College and Hospital,
Sangamner, Maharashtra, India.

Dr Suryakant Deogade
Asst Professor
Govt. Dental College and
Hospital Nagpur, Maharashtra
India.

Reeta Patait
Esthetic Dental Surgeon,
Multicare Dental Clinic, Nashik,
Maharashtra, India.

Amol Thorat
Prof Head Dept Prosthodontia,
Aditya Dental College and
Hospital, Beed Maharashtra,
India.

Priyanka Singh
Post Graduate Student, Dept of
oral Medicine and Radiology
SMBT Dental College and
Hospital, Sangamner,
Maharashtra, India.

Correspondence

Mahendra R Patait
Prof Head Dept of Oral Medicine
and Radiology, SMBT Dental
College and Hospital,
Sangamner, Maharashtra, India.

International Journal of Physical Education, Sports and Health

Management of avulsed central incisor in mixed dentition

**Mahendra R Patait, Dr. Suryakant Deogadhe, Reeta Patait, Amol Thorat
and Priyanka Singh**

Abstract

Sports injuries to the mouth and oral environment can be disfiguring and costly, both financially and in terms of athletes time away from school, work or training. And can become expensive, depending upon the nature and extent of the trauma. The purpose of clinical study is Reimplantation technique used in the treatment of avulsed case. This case report is related to an avulsed tooth and its management in case of a 10 year old cricket player boy.

Keywords: Avulsed, Mixed Dentition, Primary teeth.

1. Introduction

Traumatic injuries of the dento-alveolar region among children are unfortunate, and often remain ignored. Management of children with injuries to their anterior tooth/teeth, and dealing with their concerned parents is a challenging task for the dentist. There is perhaps no single dental disturbance that has a greater psychological impact on both parents and the child than the fracture or loss of a child's anterior tooth. Literature reports a 4-46% incidence of traumatic anterior teeth injuries [3]. Children in the age group of 1 to 2 1/2 years most commonly sustain injuries to the primary teeth, while those in the age group from 7 to 11 years show high prevalence of injuries to the permanent teeth. Boys are more susceptible than girls in sustaining injuries [1]. The most common tooth to be involved is maxillary central incisor, followed by mandibular central, mandibular lateral and maxillary lateral incisors being the least common [2].

2. Case Report

A 11 year old boy reported to the Multicare Dental Clinic with history of loss of upper front tooth due to fall while playing on the previous evening. The Patient presented with pain that was Partially relieved by medication given by general physician. The tooth had been preserved in normal water as advised by the physician. The patient gave H/O slight Bleeding from the upper lip. During examination the patient was seen to be well oriented, co operative and did not give any history of Unconsciousness, vomiting or nasal bleeding. Extra oral examination revealed slightly swollen reddish edematous upper lip with minor lacerations on upper and lower labial mucosa. On intra oral examination, the following findings were recorded.

- Traumatically avulsed maxillary right central incisor (11) region with healing fresh socket.
- Slight discomfort and grade I mobility in association with maxillary left central incisor (21) without any visible fracture.
- Occlusion of patient appeared to be normal.

3. Management

The upper and lower lips were carefully cleaned with betadine scrub and IOPA was taken in the region of maxillary right central incisor --- and left central incisor. On IOPA socket OF 11 area appears clear without any labial or palatal bony plate fracture. 21 region showed slight uniform periodontal thickening was observed. The completely avulsed 11 was carefully removed from the water with tweezer and radiograph was taken, which showed root completion without any hair line root fracture.

As the tooth appeared completely normal - root canal treatment for the avulsed tooth was planned outside the oral cavity. Root Canal Treatment of 11 was completed using the conventional technique. Glass-ionomer cement was used as the post obturation restorative material. After completion of root canal post operative radiograph was taken. With the help of moons probe small bleeding was induced in fresh healing socket of 11. root canal treated (11) was gently inserted in to the socket by taking the gingival margin into consideration. With the support of adjacent teeth, acid-etch resin with soft arch wire splinting was done. After 3 weeks the splinting was removed, postoperative radiograph was taken and the patient was advised full ceramic crown. Follow up radiograph of 11 region after 9 yrs shows no pathology.

4. Discussion

Replantation is the technique in which a tooth, usually one in the anterior region is reinserted into the alveolus after its loss or displacement by accidental means. Success of the replantation procedure is undoubtedly related to the length of time elapsed between the loss of tooth and its replacement in the socket⁶. The condition of the tooth, particularly the condition of the periodontal ligament tissue remaining on the root surface is also an important factor that influences the success of replantation. The sooner a tooth is replanted in its socket after avulsion, better the prognosis will be for retention without root resorption. Hanks Suffered saline, isotonic saline or pasteurized whole bovine milk⁵ may be the most favorable known storage medium for the avulsed tooth. Human saliva is an acceptable short-term substitute storage liquid⁴. Considering young age and associated psychological trauma, replacement of missing tooth with fixed prosthesis although the easiest option, cannot be regarded as the best. If extra oral dry time for avulsed tooth is less than 2 hours the tooth can be replanted immediately. If extra oral dry time is greater the tooth should be soaked in a topical fluoride for 5 - 20 minutes, rinsed with saline and then replanted. If the tooth has been in any physiological storage media (such as H.B.S.S., milk, or saline), it should be replanted immediately.

4.1 Recommended Guidelines of the American Association of Endodontics

4.1.1 Tooth with open apex (divergent apex) and less than 2 hours extraoral dry time

- a. Replant in an attempt to revitalize the pulp.
- b. Recall patient every 3-4 weeks for evidence of pathosis.
- c. If pathosis is noted, thoroughly clean and fill the canal with calcium hydroxide (apexification procedure)

4.1.2 Tooth with open apex (divergent apex) and greater than 2 hours extraoral dry time

- a. Thoroughly clean and fill the canal with calcium hydroxide.
- b. Recall the patient in 6 - 8 weeks.

4.1.3 Tooth with partially to completely closed apex and less than 2 hours extraoral dry time

- a. Remove the pulp in 7-14 days.
- b. Medicate the canal with calcium hydroxide.
- c. Obturate canal with gutta percha and sealer after 7-14 days of calcium hydroxide

4.1.4 Tooth with partially to completely closed apex and greater than 2 hours extraoral dry time

- a. Perform root canal therapy either intraorally or extraorally.

- b. If treated extraorally, avoid chemical or mechanical damage to root surface.

4.2 Restoration of the Avulsed Tooth.

4.2.1 Recommended Temporary Restorations (placed prior to final obturation)

1. Reinforced zinc oxide eugenol.
2. Acid etch/composite resin.

4.2.2 Recommended Permanent Restorations (placed immediately after final obturation)

1. Dentin bonding agent.
2. Acid etch composite resin

4.3 Home care

- a. No biting on splinted teeth
- b. Soft diet
- c. Maintenance of good oral hygiene

4.4 Pharmacotherapy

- Systemic antibiotics
- Referral to physician for tetanus consultation within 48 hours
- Chlorhexidine rinses
- Analgesics

4.5 Additional Considerations

- A. Avulsed primary teeth should not be replanted.
- B. Avulsed permanent teeth require follow up evaluations for a minimum of 2- 3 years to determine the outcome of therapy.
- C. Inflammatory resorption, replacement resorption, ankylosis, and tooth submergence are potential complications when avulsed teeth are replanted.

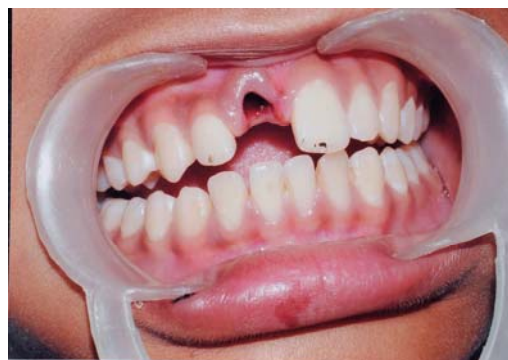

Fig 1: preoperative photo



Fig 2: Avulsed tooth

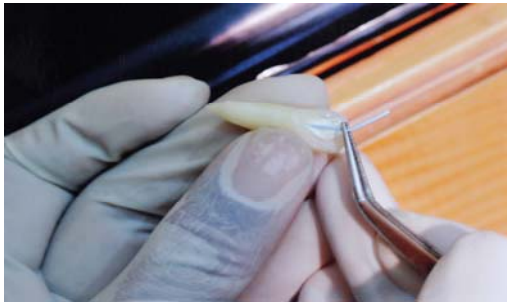


Fig 3: Conventional RCT

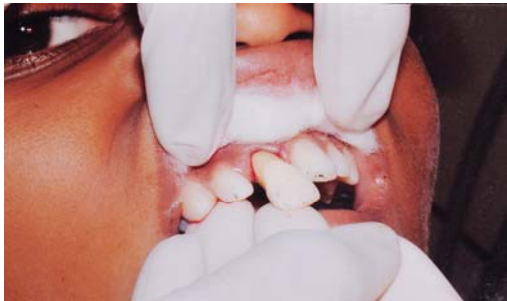

Fig 4: Replantation of tooth

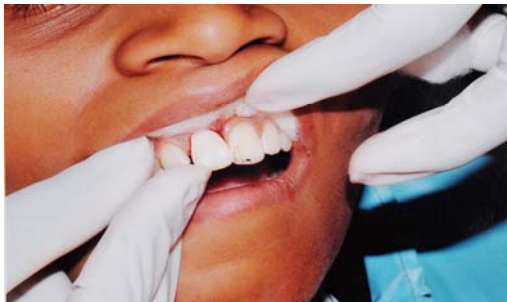

Fig 5: Positioning of Replanted tooth

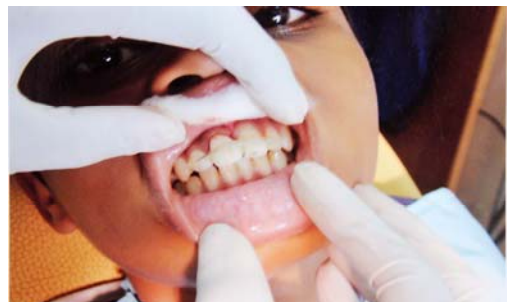

Fig: Splinting with orthodontic wire.

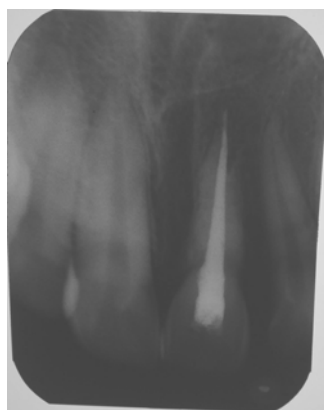

Fig: Post – Operative Radiograph after 9 yrs.

5. Conclusion

The replanted tooth serves as a space maintainer and often guides adjacent tooth into their proper positioning in the arch, a function that is important during the transitional dentition period. If a child and the parents are cooperative and made to understand it could be possible, to carry out ideal procedures like RCT on the tooth outside the oral cavity followed by splinting which may take longer time and warrant tremendous amount of cooperation but the final result will be far better than fixed prosthesis.

This article affirms the fact that even children as dental patients can be co operative for such an extensive and time-consuming treatment plan for saving a natural anterior tooth.

6. References

1. Camp JH: Replantation of teeth following trauma. In McDonald RE and others edition; Current therapy in dentistry St Louis mosby, 1980, 7.
2. SG. Damle - Textbook of Pediatric Dentistry 2nd edition Arya Publishing house, 332.
3. Anderson JO, Hjorting – Hansen E. Replantation of teeth, Radiographic & clinical study of 110 human that replanted after accidental loss, Acta odontol Scand. 24; 263:287-1989
4. Blomlof L, Otteskuq P, Hammarstrom L. Effect of storage in media with different ion strength and osmolarity on human periodontal ligament cells. Scand J Dent Res. 1981; 89:180-187.
5. Coyrfs FI, Muller WA, Tabelaing HJ. Milk as an interim storage medium for avulsed teeth. Pediat Dent 1983; 5:183-186.
6. Barry GN. Replanted teeth still functioning after 42 years: Report of case, IADA 1976; 94:412-413.